HOKKAIDO UNIVERSITY

Title	Application of collagen hydrogel/sponge scaffold facilitates periodontal wound healing in class II furcation defects in beagle dogs
Author(s)	Kosen, Yuta; Miyaji, Hirofumi; Kato, Akihito et al.
Citation	Journal of Periodontal Research, 47(5), 626-634 https://doi.org/10.1111/j.1600-0765.2012.01475.x
Issue Date	2012-10
Doc URL	https://hdl.handle.net/2115/62510
Rights	This is the peer reviewed version of the following article: [Application of collagen hydrogel/sponge scaffold facilitates periodontal wound healing in class II furcation defects in beagle dogs], which has been published in final form at [http://dx.doi.org/10.1111/j.1600-0765.2012.01475.x]. This article may be used for non-commercial purposes in accordance with Wiley Terms and Conditions for Self-Archiving.
Type	journal article
File Information	JPR manuscript Kosen.pdf

Hokkaido University Collection of Scholarly and Academic Papers : HUSCAP

Application of collagen hydrogel/sponge scaffold facilitates periodontal wound healing in class II furcation defects in beagle dogs

Yuta KOSEN, Hirofumi MIYAJI, Akihito KATO, Tsutomu SUGAYA, Masamitsu KAWANAMI

Institutions

Department of Periodontology and Endodontology, Division of Oral Health Science, Hokkaido University Graduate School of Dental Medicine, Sapporo, Japan

Address

Department of Periodontology and Endodontology, Division of Oral Health Science, Hokkaido University Graduate School of Dental Medicine, N13 W7 Kita-ku, Sapporo 060-8586, Japan.

Running title

Periodontal healing by hydrogel scaffold

Key words

Collagen hydrogel/sponge scaffold; periodontal wound healing; class II furcation infrabony defects; dog.

Correspondence address

Hirofumi MIYAJI.

Department of Periodontology and Endodontology, Division of Oral Health Science, Hokkaido University Graduate School of Dental Medicine, N13 W7 Kita-ku, Sapporo 060-8586, Japan.

Abstract

Background and objective: A three-dimensional scaffold may play an important role in periodontal tissue engineering. We prepared bio-safe collagen hydrogel which exhibited properties similar to those of native extracellular matrix. The aim of this study was to examine the effect of implantation of collagen hydrogel/sponge scaffold on periodontal wound healing in class II furcation defects in dogs.

Materials and methods: Collagen hydrogel/sponge scaffold was prepared by injecting collagen hydrogel cross-linked by ascorbate-copper ion system into a collagen sponge. Class II furcation defects (5 mm depth, 3 mm width) were surgically created in beagle dogs. The exposed root surface was planed and demineralized with EDTA. In the experimental group, the defect was filled with collagen hydrogel/sponge scaffold. In the control group, no implantation was performed. Histometric parameters were evaluated 2 and 4 wk after surgery.

Results: At 2 wk, the collagen hydrogel/sponge scaffold displayed high biocompatibility and biodegradability with numerous cells infiltrating the scaffold. In the experimental group, reconstruction of alveolar bone and cementum was frequently observed 4 wk after surgery. Periodontal ligament tissue was also reestablished between alveolar bone and cementum. Volumes of new bone, new cementum and new periodontal ligament in the experimental group were significantly greater than those of the control group. In addition, epithelial downgrowth was suppressed by collagen hydrogel application.

Conclusion: The collagen hydrogel/sponge scaffold possessed high tissue compatibility and degradability. Implantation of the scaffold facilitated periodontal wound healing in class II furcation defects in beagle dogs.

Key words

Collagen hydrogel/sponge scaffold, Periodontal wound healing, Class II furcation defects, Dog

Introduction

In periodontal therapy, proliferation and migration of periodontal ligament cells and bone-derived cells play a key role in reconstruction of functional periodontal tissue following surgical treatment. A three-dimensional scaffold, an important element of tissue engineering, has been prepared with this objective. The hydrogel is a hydrated polymer material consisting of copolymers of synthetic and/or natural polymers, and has mechanical and structural properties resembling native extracellular matrix, and degradability favorable for use as a scaffold (1). Hydrogel scaffolds using various materials such as agarose (2), alginate (3), chitosan (4,5), hyaluronic acid (6), short oligopeptides (7,8) and collagen (9) were used in previous studies. It was reported that *in vitro* proliferation and adhesion of osteoblasts, fibroblasts, vascular endothelial cells and chondrocytes were stimulated in three-dimensional culture using hydrogel (10-14), suggesting that the hydrogel served as an effective scaffold for cells associated with bone tissue engineering. Furthermore, an *in vivo* study showed that application of alginate hydrogel, hyaluronic acid and rat calvarial osteoblasts enhanced ectopic bone induction in rat back skin (15). Scaffolds using hydrogel are expected to be widely used for clinical trials (16-18).

Recently, type I collagen hydrogel treated by cross-linking with an ascorbate-copper ion system was prepared (19,20). Type I collagen is the major component of connective tissue and bone extracellular matrix. In a skin defect of guinea pig, implantation of the collagen hydrogel promoted migration of fibroblasts, macrophages and vascular endothelial cells into the hydrogel, which facilitated wound healing of the skin defect (21). Furthermore, bio-safe profiles; no toxicity and no chronic inflammatory response, were reported in previous studies of collagen hydrogel implantation (22).

However, hydrogels cross-linked by ascorbate-copper ion system do not possess mechanical strength due to their high fluidity. In case of three-dimensional periodontal tissue defects, it is difficult to retain the collagen hydrogel in the defect. Therefore, a collagen hydrogel/sponge scaffold was prepared by injecting collagen hydrogel to fill spaces in the collagen sponge (23), which has mechanical stiffness. We recently observed the combined effect of cell proliferative activity of the collagen hydrogel and space maintenance by the collagen sponge used for bone augmentation in rats (24). Thus, we hypothesized that periodontal tissue would be formed on application of collagen hydrogel/sponge scaffold in a periodontal defect because hydrogel can be retained in the defect and stimulate periodontal cell growth and migration. However, in large periodontal defects, the effect of collagen hydrogel scaffold on periodontal wound

healing has not yet been investigated. The aim of present study was to evaluate histologically whether collagen hydrogel/sponge scaffold implant facilitated wound healing of periodontal tissue in class II furcation defects.

Materials and Methods

Preparation of collagen hydrogel and sponge

Collagen hydrogel was prepared from atelocollagen derived from calf skin dermis (Koken, Tokyo, Japan). Atelocollagen solution was stirred with 1 M HCl and stored at 10°C as long as 3 days. Subsequently, 1 mM L(+)-ascorbic acid and 0.1 mM $CuCl_2$ were added to this solution and adjusted to a final concentration of 1.5% for collagen hydrogel (Fig. 1-A).

Collagen sponge was provided by Olympus Terumo Biomaterials (Tokyo, Japan). Atelocollagen in a dilute HCl solution (pH 3.0) was neutralized by adding concentrated phosphate buffer in NaCl to a final concentration of 0.1% collagen, 30 mM Na_2HPO_4 and 0.1 M NaCl. This collagen solution was incubated at 37°C for 4 hours. The resulting fibrous precipitate was referred to as fibrillar collagen (FC). Heat-denatured collagen (HAC) was prepared from atelocollagen in a dilute HCl solution by heating at 60°C for 30 minutes. A composite of FC and HAC was prepared by mixing the two at a ratio of 9:1 (w/w), respectively. This composite material was adjusted to a final concentration of 4% and made into the form of a sponge by lyophilization at -30°C. This sponge was dehydrothermally cross-linked at 110°C for 2 hours and used as a collagen sponge. In this study, 30 pieces of collagen sponge of size 5 × 3 × 3 mm were used (Fig. 1-B).

Preparation and morphological analysis of collagen hydrogel/sponge scaffold

The collagen hydrogel/sponge scaffold was prepared as follows: collagen hydrogel (100 μl) was injected into the block of collagen sponge under vacuum (Fig. 1-C). Subsequently, collagen hydrogel/sponge scaffold was fixed in 10% buffered formalin and embedded in paraffin for morphological analysis. Sections (6 μm thick) were prepared, stained with hematoxylin and eosin (HE) and examined using light microscopy.

Animals

Three healthy female beagle dogs, 12-16 months old and weighing approximately 10 kg, were used in this experiment. The experimental protocol followed the institutional animal use and care regulations of Hokkaido University (Animal Research

Committee of Hokkaido University, Approval No. 08-0255). Surgical procedures were performed under general anesthesia with medetomidine hydrochloride (0.1 ml/kg, Domitor, Nippon Zenyaku Kogyo, Koriyama, Japan) and butorphanol tartrate (0.1 ml/kg, Vetorphale, Meiji Seika, Tokyo, Japan), and local anesthesia with lidocaine hydrochloride (2% with 1:80,000 epinephrine, Xylocaine, Dentsply-sankin, Tokyo, Japan).

Surgical procedure

After reflection of a buccal muco-gingival partial thickness flap, the periosteum was removed from alveolar bone. Class II buccal furcation defects (5 mm in height, 3 mm in width) were surgically created at the maxillary second and third premolars and mandibular second, third and fourth premolars (Fig. 2-A). The root surface facing the defect was planed to remove cementum. Reference notches indicating the bottom of the defect were prepared on the root surfaces. Three premolars were eliminated from this study because of anatomical problems such as a narrow furcation area. Twenty-seven class II furcation defects were thus created and randomly assigned to the experimental and control groups. Subsequently, the denuded root surface was demineralized with 24% EDTA (pH 7.0) for 3 minutes and washed with saline. In the experimental group, the defect was filled with collagen hydrogel/sponge scaffold (Fig. 2-B) and the flap was repositioned and securely sutured (Surgilon, Tyco Healthcare Japan, Tokyo, Japan; Fig. 2-C). In the control group, the flap was closely sutured with no implantation of collagen material. The animals received ampicillin sodium (300 mg/kg, Viccillin, Meiji Seika, Tokyo, Japan) daily for 3 days and a plaque control regimen with 0.5% chlorhexidine twice weekly for the entire period of the experiment.

Histological procedure

The animals were euthanized using an overdose of sodium pentobarbital (0.5 ml/kg, Somnopentyl, Kyoritsu, Tokyo, Japan) following general anesthesia with medetomidine hydrochloride (0.1 ml/kg) and butorphanol tartrate (0.1 ml/kg). Specimens were collected from the wound 2 and 4 wk post-surgery. The tissue blocks, including teeth, bone and soft tissue, were fixed in 10% buffered formalin, decalcified in 10% formic-citric acid, and embedded in paraffin wax. Sections (6 μm thick) along the mesio-distal plane were serially prepared and stained with HE and Masson’s trichrome.

Histomorphometric analysis

Five HE-stained sections were selected from each specimen; one from the mid-section of the furcation defect, and the other four from sections located every 120 μm in a buccal direction from the central plane. The following seven histomorphometric measurements were performed for each stained section using a software package (Image J 1.41, National Institute of Health, Bethesda, MD, USA):

1. Defect area: The gross area from the furcation fornix to the apical border of the notch on the mesial and distal roots.
2. Defect length: Length of the root surface between the notches on the mesial and distal roots.
3. New bone: Percentage of the area of newly formed alveolar bone in relation to the defect area.
4. New cementum: Percentage of the length of the newly formed cementum-like tissue on the root surface in relation to the defect length.
5. New periodontal ligament: Percentage of the length of functional fibrous tissue between the newly formed cementum-like tissue and alveolar bone in relation to the defect length.
6. Connective tissue: Percentage of the area of newly formed connective tissue in relation to the defect area.
7. Junctional epithelium: Percentage of the length of epithelium and non-filled area in relation to the defect length.

In the experimental group, the area of residual collagen hydrogel-sponge scaffold was measured as follows: Percentage of the area of residual collagen material in relation to the defect area.

Statistical analysis

The means and standard deviations of each parameter were calculated for two groups. Differences between the groups were analyzed using two-way ANOVA and student-t test. P-values < 0.05 were considered statistically significant. All statistical procedures were performed using a software package (DR.SPSS 11.0, SPSS Japan, Tokyo, Japan).

Results

Histological observations of collagen hydrogel/sponge scaffold

The collagen hydrogel was present as an amorphous structure and had fully penetrated into the collagen sponge under microscopy (Fig. 1-D).

Histological observations of the control group

At 2 wk, the furcation defect was mostly filled with granulation tissue composed of infiltrating fibroblastic cells, inflammatory cells and blood vessels. Formation of bone and cementum continuous with the original tissue was limited to the bottom area of the furcation defect (Fig. 4-A). In the coronal portion, there was no evidence of cementum and periodontal ligament formation (Fig. 4-B), whereas downgrowth of the junctional epithelium was prominent (Fig. 4-C). At 4 wk, further coronal extension of reformed alveolar bone was noted (Fig. 5-A). Formation of periodontal ligament between the new bone and cementum was mainly localized in the apical portion of the furcation defect (Fig. 5-B). In the coronal portion, although the connective tissue which filled the furcation defect was fibrous, there was no evidence of an oriented fiber structure associated with periodontal ligament on the root surface (Fig. 5-C). Ankylosis and root resorption were not seen at any time point.

Histological observations of the experimental group

At 2 wk, the furcation defect was occupied by cell-rich connective tissue containing many blood vessels. Alveolar bone had actively formed continuous with pre-existing bone of the apical portion (Fig. 6-A). New bone was composed of narrow trabeculae including osteoblasts, osteocytes. Formation of new cementum was confined to the space of the surgical notch, while in the coronal portion, fibrous and cellular connective tissue faced the instrumented root surfaces and cementum-like tissue was rarely formed (Fig. 6-B). However, epithelial cell invasion in the coronal portion was rarely observed even on the buccal side of the specimen. Residual collagen hydrogel/sponge scaffold were fractionated by newly formed connective tissue. As a result, several fibroblastic and osteoblastic cells had proliferated in the inner side of the collagen hydrogel material. Few inflammatory cells were also seen around the residual collagen hydrogel/sponge scaffold (Fig. 6-C).

At 4 wk, considerable new bone formation continuous with the pre-existing bone was observed in the defect area compared to the 2-wk and control specimens (Fig. 7-A). Bone regeneration was noted not only in the mid region of the furcation defect, but more towards the buccal area in serial histological sections. Development of trabecular bone containing osteoblasts and bone marrow was evident. In addition, we found that periodontal tissue healing was facilitated in the coronal and buccal portion of the furcation defect in which collagen hydrogel/sponge scaffold was implanted. Importantly, synchronous formation of periodontal ligament with physiological width and alveolar bone was exhibited. We frequently detected thin cementum-like cellular tissue on the

instrumented root surface continuous with the original cementum. Sharpey's fibers inserting into both the new cementum-like tissue and alveolar bone were seen, indicating that functionally oriented periodontal ligament tissue was reestablished (Fig. 7-B, C). Intensely-stained collagen fibers oriented perpendicularly to the root were frequently observed (Fig. 7-D). Residual hydrogel material and epithelial downgrowth were rarely noted. There were no instances of ankylosis and root resorption.

Histomorphometric analysis

The degree of periodontal healing in class II furcation defects is presented in Table 1. Application of collagen hydrogel-sponge scaffold to furcation defects accelerated periodontal wound healing. There were significant differences in the amount of newly formed alveolar bone, cementum and periodontal ligament between experimental and control groups. In specimens which received hydrogel scaffold, 45% of the periodontal tissue required for stable attachment had been reconstructed at 4 wk, which was approximately 1.5-fold greater than that of the control group. On the other hand, in the central plane 2 wk after surgery, epithelial downgrowth was evident in six defect sites in the control group (6/6), and no furcation defect site in the experimental group (0/7). Furthermore, length of the junctional epithelium in the experimental group was significantly less than that in the control group at any time point. Application of collagen hydrogel/sponge scaffold suppressed epithelial cell growth. In addition, collagen material was rarely found in the 4-wk specimens, indicating that the scaffold exhibited high degradability.

In addition, we selected two sections, one was chosen from the central plane and the other 480 μm from the central plane in a buccal direction, to examine the extent of periodontal healing in class II furcation involvement, as shown in Table 2. In the central region of furcation defect, both groups exhibited formation of new bone, cementum and periodontal ligament associated with periodontal attachment. However, in the buccal plane, these parameters of periodontal healing in the control group were significantly lower than those in the experimental group. Implantation of collagen scaffold resulted in rapid periodontal healing even in the absence of pre-existing buccal alveolar bone wall. In contrast, the control group showed downgrowth of junctional epithelium in both central and buccal planes, which was significantly greater compared to the experimental group. Growth of epithelial tissue was greatly suppressed by implantation of collagen scaffold.

Discussion

The present study focused on periodontal wound healing following implantation of collagen hydrogel scaffold in class II furcation defects. Histological findings revealed that a large number of cells, such as fibroblastic and osteoblastic cells, and a high incidence of vascularization were found in the defect space after degradation of collagen hydrogel materials. A previous study reported that following application of sponge form collagen scaffold *in vivo*, early cell growth was rarely observed in the inner part of the material, and it was limited to the peripheral area of scaffold, suggesting that infiltration of tissue-forming cells into the collagen sponge, especially into the central region, might be inhibited (25). It seems likely that lack of angiogenesis and nutritional factors in the inner area of the material makes it difficult to control the penetration of reforming tissue into the scaffold. In general, hydrogels possess water absorption properties similar to physiological extracellular matrix; the collagen hydrogel could also retain water in a 20- to 200-fold range of the empty weight (1,19). A water-absorbable material would be beneficial in the healing of tissue, because the regenerative space could retain tissue interstitial fluid which contains several growth and nutritional factors that promote angiogenesis and tissue healing. Therefore, collagen hydrogel would stimulate proliferation of periodontal cells and immediately allow cell infiltration into the inner side of the scaffold following surgical application. As a result, periodontal tissue reconstruction occurred at the most buccal region of the furcation defect as well as the central region of the histological specimens, suggesting that collagen hydrogel implantation promoted early tissue growth in a forward to buccal direction within the periodontal furcation defect.

Collagen is known to be an effective substrate for mineralization. Many investigators demonstrated that collagen application facilitated osteoblastic differentiation; expression of various osteogenic markers, and bone formation in animal studies (26,27). In the experimental group receiving collagen hydrogel implant, woven bone induction was displayed at 2 wk. Therefore, we speculate that the implanted collagen matrix in hydrogel promotes growth and differentiation of cells derived from alveolar bone and consequently enhances alveolar bone augmentation. On the other hand, in periodontal regenerative therapy, simultaneous formation of both alveolar bone and periodontal ligament play an important role in achieving a stable periodontal attachment. However, many periodontal regenerative studies using potent osteogenic factors found evidence of ankylosis on part of the root surface with alveolar bone formation and poor periodontal ligament structure, indicating that cells and extracellular matrix were poorly distributed at the interface of root and alveolar bone (28-30). The present study showed that cell-rich connective tissue had reformed along the root

surfaces after hydrogel application. In addition, the 4-wk specimens in the hydrogel applied group showed no ankylosis and the newly formed periodontal ligament showed functional morphology, connecting newly formed cementum and alveolar bone by oriented fibers, like Sharpey's fibers. Hidaka et al. (31) reported that the alkaline phosphatase activity of periodontal ligament cells was promoted in three-dimensional cell culture using collagen gel, suggesting that physiological function of periodontal ligament cell was modulated by collagen matrix. Supposedly, collagen hydrogel scaffold accelerates formation of periodontal ligament and cementum on the root surface. This material which induces periodontal ligament formation onto the instrumented root surface could be employed in future therapeutic protocols for periodontitis.

In periodontal therapy, it is believed that repopulation of mesenchymal cells originating from periodontal tissue are preferable for wound healing. However, rapid epithelial cell downgrowth along the root surface from the coronal portion frequently intervenes to prevent development of the tooth-supporting unit in the early healing stage (32). Agents used for dentin demineralization could remove the surface smear layer and expose the organic components such as collagen matrix (33). It has been demonstrated that downgrowth of junctional epithelium is suppressed by root surface demineralization (34), probably because the presence of exposed collagen matrix on the surface promotes attachment of periodontal fibroblasts. In this investigation, the EDTA-treated root surface in the experimental group was supplemented with collagen matrix from collagen hydrogel scaffold. Furthermore, migration of periodontal fibroblasts might be regulated by absence of extracellular matrix. Fibroblasts derived from the periodontal ligament and gingival connective tissue were allowed to migrate in a tissue-culture flask coated with type I collagen (35). Thus, it seems likely that collagen hydrogel application enabled bio-modification of the root surface as a molecular regulator of cell movement and consequently suppressed invasion of epithelium.

A regenerative scaffold requires rapid replacement with low cytotoxicity following tissue growth in the healing site. Type I collagen, which is a biocompatible substance, has been widely used as a tissue graft (36,37). Ishikawa et al. (19) succeeded in preparing a highly bio-safe collagen hydrogel with a different cross-linking method in which collagen solution was incubated with ascorbate and copper ion. The sponge form collagen used in this study; FC- HAC sponge, possessed high tissue compatibility and is widely used as artificial skin (23). In the experimental group at 2 wk, inflammatory cell infiltration was infrequently observed around the collagen hydrogel/sponge scaffold, suggesting that the scaffold was a biocompatible material.

The high degradability of the collagen hydrogel/sponge scaffold was also demonstrated in this study. Adequate replacing ability of collagen material would allow early periodontal tissue formation due to early exchange of space between the degrading scaffold and periodontal cells.

The amount of regenerated periodontal tissue should be augmented when using the collagen hydrogel/sponge scaffold for a more stable and predictable periodontal healing. Adjunctive therapies with growth factors including fibroblast growth factor-2 and bone morphogenetic proteins were attempted to create periodontal tissue lost by advanced periodontitis (38-40). On the other hand, it is well known that tissue regeneration can be promoted using a viable cell transplantation method (41). In particular, cell sheets are advantageous, as a large number of cells can be easily transplanted (42,43). Periodontal regeneration resulting from hydrogel scaffold use with additional methods is an important point to be verified in the future.

In conclusion, application of the collagen hydrogel/sponge scaffold in class II furcation defects facilitated periodontal wound healing and inhibited epithelial downgrowth, contributing to reformation of a structural unit of periodontal attachment.

Acknowledgements

We are grateful to our colleagues Drs. Saori Tanaka Ph.D, Ryosuke Ishizuka Ph.D, Naoko Kobayashi Ph.D, Masaru Henmi Ph.D, and Mr. Hiroyuki Yokoyama for their assistance. We thank Olympus Terumo Biomaterials Corp. for providing the FC-HAC sponge. This work was supported by Grants-in-Aid for Young Scientists B (19791606 and 22791916) from the Ministry of Education, Culture, Sports, Science and Technology. The authors report no conflicts of interest related to this study. This paper was presented as an examination thesis at Hokkaido University.

References

1. Park JB. The use of hydrogels in bone-tissue engineering. *Med Oral Patol Oral Cir Bucal* 2011; **16:** 115-118.
2. Yoshida M, Babensee JE. Differential effects of agarose and poly (lactic-co-glycolic acid) on dendritic cell maturation. *J Biomed Mater Res A* 2006; **79:** 393-408.
3. Barralet JE, Wang L, Lawson M, Triffitt JT, Cooper PR, SheltonRM. Comparison of bone marrow cell growth on 2D and 3D alginate hydrogels. *J Mater Sci Mater Med* 2005; **16:** 515-519.
4. Kong L, Ao Q, Wang A, et al. Preparation and characterization of a multilayer biomimetic scaffold for bone tissue engineering. *J Biomater* 2007; **22:** 223-239.
5. Hong Y, Mao Z, Wang H, Gao C, Shen J. Covalently crosslinked chitosan hydrogel formed at neutral pH and body temperature. *J Biomed Mater Res A* 2006; **79:** 913-922.
6. Cui FZ, Tian WM, Hou SP, Xu QY, Lee IS. Hyaluronic acid hydrogel immobilized with RGD peptides for brain tissue engineering. *J Mater Sci Mater Med* 2006; **17:** 1393-1401.
7. Temenoff JS, Park H, Jabbari E, et al. In vitro osteogenic differentiation of marrow stromal cells encapsulated in biodegradable hydrogels. *J Biomed Mater Res A* 2004; **70:** 235-244.
8. Park H, Temenoff JS, Tabata Y, et al. Effect of dual growth factor delivery on chondrogenic differentiation of rabbit marrow mesenchymal stem cells encapsulated in injectable hydrogel composites. *J Biomed Mater Res A* 2009; **88:** 889-897.
9. Lee CH, Singla A, Lee Y. Biomedical applications of collagen. *Int J Pharm* 2001; **221:** 1-22.
10. Narmoneva DA, Vukmirovic R, Davis ME, Kamm RD, Lee RT. Endothelial cells promote cardiac myocyte survival and spatial reorganization: implications for cardiac regeneration. *Circulation*. 2004; **110:**962-968.
11. Narmoneva DA, Oni O, Sieminski AL, et al. Self-assembling short oligopeptides and the promotion of angiogenesis. *Biomaterials*. 2005; **26:** 4837-4846.
12. Genove E, Shen C, Zhang S, Semino CE. The effect of functionalized

self-assembling peptide scaffolds on human aortic endothelial cell function. *Biomaterials* 2005; **26:** 3341-3351.

13. Bokhari MA, Akay G, Zhang S, Birch MA. The enhancement of osteoblast growth and differentiation in vitro on a peptide hydrogel-poly HIPE polymer hybrid material. *Biomaterials* 2005; **26:** 5198-5208.
14. Kisiday J, Jin M, Kurz B, et al. Self-assembling peptide hydrogel fosters chondrocyte extracellular matrix production and cell division: implications for cartilage tissue repair. *Proc Natl Acad Sci U S A*. 2002; **99:** 9996-10001.
15. Hesse E, Hefferan TE, Tarara JE, et al. Collagen type I hydrogel allows migration, proliferation, and osteogenic differentiation of rat bone marrow stromal cells. *J Biomed Mater Res A*. 2010; **94:** 442-449.
16. Gelbart M, Friedman R, Burlui V, Rohrer M, Atkinson B. Maxillary sinus augmentation using a peptide-modified graft material in three mixtures: a prospective human case series of histologic and histomorphometric results. *Implant Dent* 2005; **14:** 185-193.
17. Matos SM, Guerra FA, Krauser J, Marques F, Ermida JM, Sanz M. Clinical evaluation of the combination of anorganic bovine-derived hydroxyapatite matrix/cell-binding peptide (P-15) in particulate and hydrogel form as a bone replacement graft material in human periodontal osseous defects: 6-month reentry controlled clinical study. *J Periodontol* 2007; **78:** 1855-1863.
18. Jung RE, Hälg GA, Thoma DS, Hämmerle CH. A randomized, controlled clinical trial to evaluate a new membrane for guided bone regeneration around dental implants. *Clin Oral Implants Res* 2009; **20:** 162-168.
19. Ishikawa K, Matsui R, Takano Y, Katakura T. Preparation of biodegradable hydrogel. *Jpn J Artif Organs* 1997; **26:** 791-797.
20. Kano Y, Sakano Y, Fujimoto D. Cross-linking of collagen by ascorbate-copper ion systems. *J Biochem* 1987; **102:** 839-842,.
21. Matsui R, Ishikawa K, Takano Y, Katakura T. Application of collagen hydrogel material onto model delayed closing of full-thickness skin defect wound on guinea-pig. *Jpn J Artif Organs* 1997; **26:** 772-778.
22. Miyaji H, Sugaya T, Kato K, Kawamura N, Kawanami M. The effects of collagen hydrogel implantation in buccal dehiscence defects in beagles. *J Oral Tissue Engin* 2007; **5:** 87-95.
23. Koide M, Osaki K, Konishi J, et al. A new type of biomaterial for artificial skin: Dehydrothermally cross-linked composites of fibrillar and denatured collagens. *J Biomed Mater Res* 1993; **27:** 79-87.

24. Tokunaga K, Sugaya T, Miyaji H, Kawanami M. Biological effects of collagen hydrogel-sponge composite scaffold and osteoinduction by combined application with BMP. *Jpn J Conserv Dent* 2008; **51:** 659-669.
25. Shimoji S, Miyaji H, Sugaya T, et al. Bone perforation and placement of collagen sponge facilitate bone augmentation. *J Periodontol* 2009; **80:** 505-511.
26. Mizuno M, Shindo M, Kobayashi D, Tsuruga E, Amemiya A, Kuboki Y. Osteogenesis by bone marrow stromal cells maintained on type I collagen matrix gels in vivo. *Bone* 1997; **20:**101-107.
27. Talley-Ronsholdt DJ, Lajiness E, Nagodawithana K. Transforming growth factor-beta inhibition of mineralization by neonatal rat osteoblasts in monolayer and collagen gel culture. *In Vitro Cell Dev Biol Anim* 1995; **31:** 274-282.
28. Miyaji H, Sugaya T, Kato K, Kawamura N, Tsuji H, Kawanami M. Dentin resorption and cementum-like tissue formation by bone morphogenetic protein application. *J Periodontal Res* 2006; **41:** 311-315.
29. Saito E, Saito A, Kawanami M. Favorable healing following space creation in rhBMP-2-induced periodontal regeneration of horizontal circumferential defects in dogs with experimental periodontitis. *J Periodontol* 2003; **74:** 1808-1815.
30. Stavropoulos A, Wikesjö UM. Influence of defect dimensions on periodontal wound healing/regeneration in intrabony defects following implantation of a bovine bone biomaterial and provisions for guided tissue regeneration: an experimental study in the dog. *J Clin Periodontol* 2010; **37:** 534-543.
31. Hidaka T, Kinoshita Y, Fukuoka S, Ozono S, Kato K, Ikeda Y. A Study on the behaviors of periodontal ligament cells in a gel embedded collagen culture and their suitability for implant seeding. *Jpn J Soc Biomaterials* 1997; **15:** 63-70.
32. Fernyhough W, Page RC. Attachment, growth and synthesis by human gingival fibroblasts on demineralized or fibronectintreated normal and diseased tooth roots. *J Periodontol* 1983; **54:** 133-140
33. Blomlöf J, Blomlöf L, Lindskog S. Effect of different concentrations of EDTA on smear removal and collagen exposure in periodontitis-affected root surfaces. *J Clin Periodontol*. 1997; **24:** 534-537.
34. Blomlöf J, Jansson L, Blomlöf L, Lindskog S. Root surface etching at neutral pH promotes periodontal healing. *J Clin Periodontol* 1996; **23:** 50-55.
35. Lallier TE, Miner QW Jr, Sonnier J, Spencer A. A simple cell motility assay demonstrates differential motility of human periodontal ligament fibroblasts, gingival fibroblasts, and pre-osteoblasts. *Cell Tissue Res* 2007; **328:** 339-354.
36. Abramo AC, Viola JC. Heterologous collagen matrix sponge: histologic and clinical

response to its implantation in third-degree burn injuries. *Br J Plast Surg* 1992; **45:** 117-122.

37. Suzuki S, Kawai K, Ashoori F, Morimoto N, Nishimura Y, Ikada Y. Long-term follow-up study of artificial dermis composed of outer silicone layer and inner collagen sponge. *Br J Plast Surg* 2000; **53:** 659-666.
38. Murakami S, Takayama S, Kitamura M, et al. Recombinant human basic fibroblast growth factor (bFGF) stimulates periodontal regeneration in class II furcation defects created in beagle dogs. *J Periodontal Res* 2003; **38:** 97-103.
39. Nakahara T, Nakamura T, Kobayashi E, et al. Novel approach to regeneration of periodontal tissues based on in situ tissue engineering: effects of controlled release of basic fibroblast growth factor from a sandwich membrane. *Tissue Eng* 2003; **9:** 153-162.
40. Wikesjö UM, Sorensen RG, Kinoshita A, Jian Li X, Wozney JM. Periodontal repair in dogs: effect of recombinant human bone morphogenetic protein-12 (rhBMP-12) on regeneration of alveolar bone and periodontal attachment. *J Clin Periodontol*. 2004; **31:** 662-670.
41. Inoue K, Miyaji H, Sugaya T, Kawanami M. Ectopic bone induction by BMP-loaded collagen scaffold and bone marrow stromal Cell Sheet. *J Oral Tissue Engin* 2010; **8:** 19-29
42. Nishida K, Yamato M, Hayashida Y, et al. Functional bioengineered corneal epithelial sheet grafts from corneal stem cells expanded ex vivo on a temperature-responsive cell culture surface. *Transplantation* 2004; **77:** 379-385.
43. Akizuki T, Oda S, Komaki M, et al. Application of periodontal ligament cell sheet for periodontal regeneration: a pilot study in beagle dogs. *J Periodont Res* 2005; **40:** 245-251.

Table 1. Histomorphometric analysis at 2 and 4 wk after surgery (mean ± SD).

	Control group		Experimental group	
	2 wk (n=6)	4 wk (n=7)	2 wk (n=7)	4 wk (n=7)
New bone (%)	23.7 ± 10.7	36.4 ± 5.3	26.0 ± 10.5	51.4 ± 6.4†
New cementum (%)	16.3 ± 9.0	35.2 ± 7.4	29.3 ± 5.0*	47.6 ± 7.2†
New periodontal ligament (%)	21.8 ± 12.0	35.1 ± 6.8	32.7 ± 5.9	48.3 ± 11.0†
Junctional epithelium (%)	59.9 ± 10.8	34.5 ± 8.2	10.1 ± 6.8*	13.2 ± 5.9†
Connective tissue (%)	70.3 ± 8.2	57.1 ± 5.9	68.3 ± 10.3	47.9 ± 6.2†
Residual collagen material (%)	-	-	5.4 ± 2.6	0.1 ± 0.1

* Statistical difference compared to control group at 2 wk ($p < 0.05$). † Statistical difference compared to control group at 4 wk ($p < 0.05$).

Table 2. Histomorphometric analyses of central section and buccal section positioned 480 µm from the central plane in the buccal direction at 4 wk after surgery (mean ± SD).

	Central sections		Buccal sections	
	Control group	Experimental group	Control group	Experimental group
New bone (%)	59.6 ± 12.1	68.5 ± 16.1	19.7 ± 7.4	41.1 ± 8.8†
New cementum (%)	47.1 ± 6.7	52.3 ± 11.8	17.7 ± 13.0	41.3 ± 9.7†
New periodontal ligament (%)	59.2 ± 16.9	68.9 ± 15.2	18.0 ± 6.5	48.3 ± 5.5†
Junctional epithelium (%)	21.4 ± 5.9	4.9 ± 0.8*	55.3 ± 9.6	24.0 ± 6.3†
Connective tissue (%)	37.1 ± 12.6	31.2 ± 15.5	70.2 ± 11.9	56.7 ± 7.1†
Residual collagen material (%)	-	0.3 ± 0.8	-	0.0 ± 0.0

* Statistical difference compared to central section of control group ($p < 0.05$). † Statistical difference compared to buccal section of control group ($p < 0.05$).

Figure legends

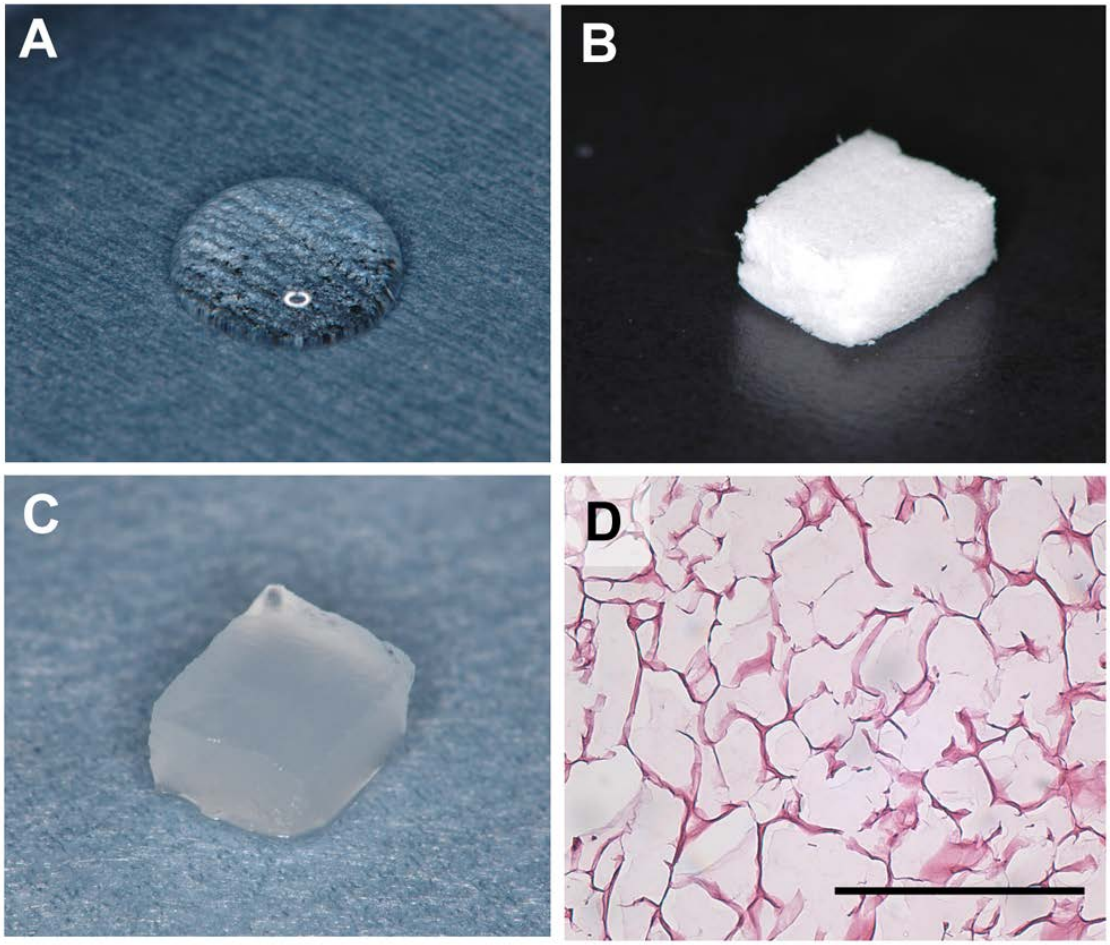

Figure 1. A) Collagen hydrogel. B) Collagen sponge. C) Collagen hydrogel/sponge scaffold. D) HE staining of collagen hydrogel/sponge scaffold. (scale bar: D = 100 µm)

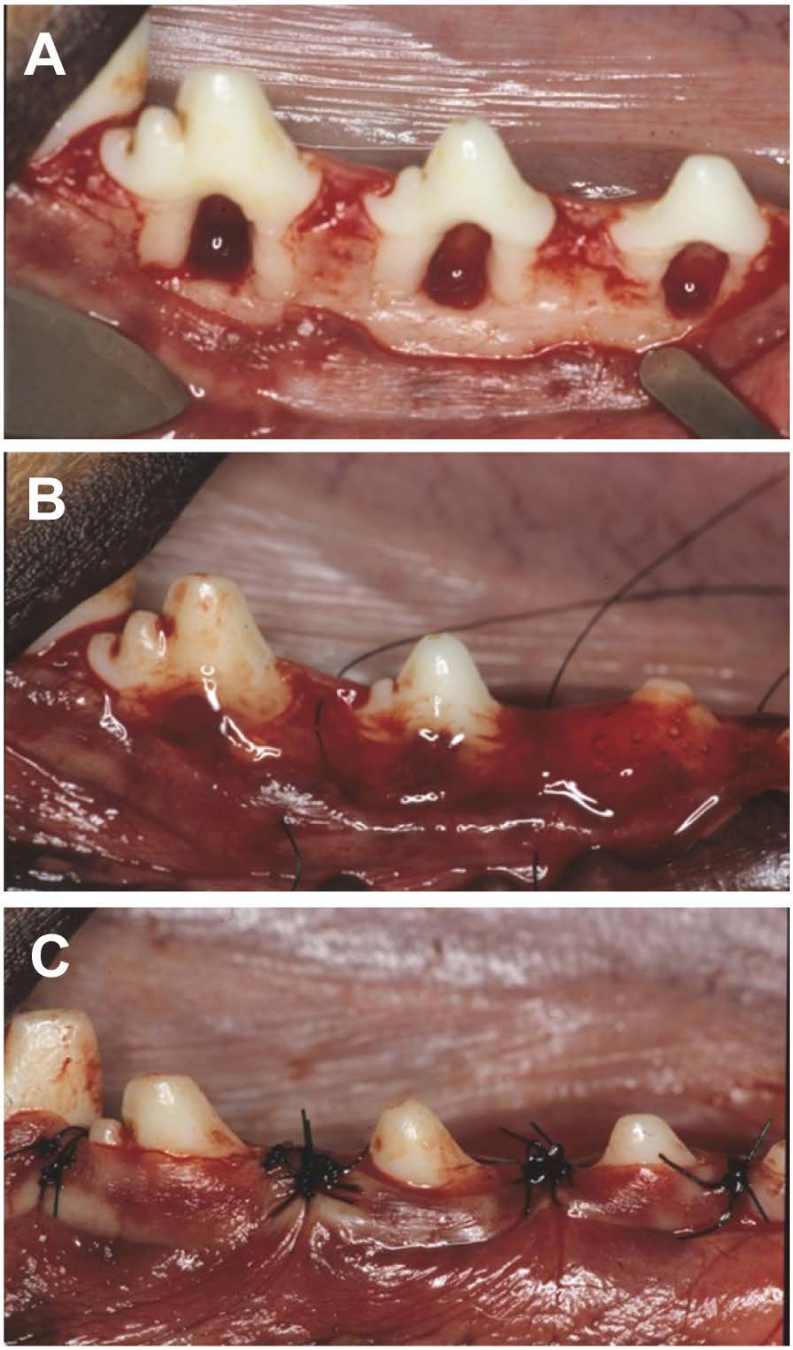

Figure 2. A) After the flap was elevated, a class II furcation defect was surgically created. B) The defect was filled with collagen hydrogel-sponge scaffold. C) The flap was repositioned and securely sutured.

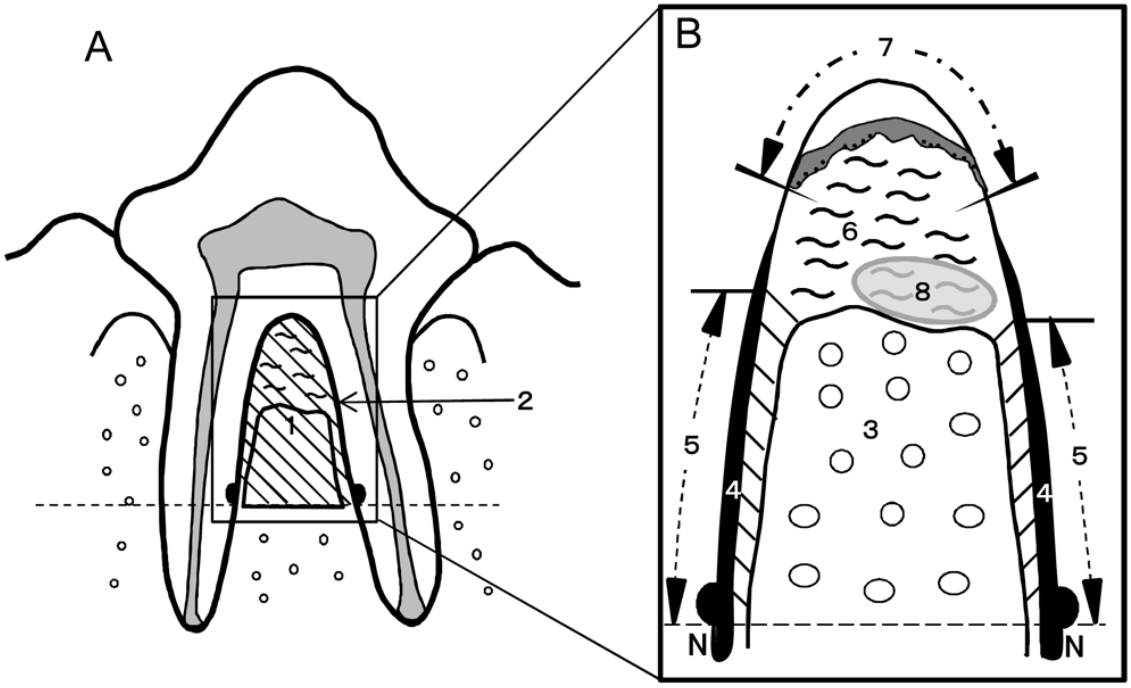

Figure 3. Schematic drawing of histomorphometric analysis of periodontal wound healing. A) Mesio-distal view of the experimental tooth indicating furcation defect area (1) and defect length (2). B) Magnification of the furcation view indicating the following parameters: area of new bone (3), length of new cementum-like tissue (4), length of periodontal ligament (5), area of connective tissue (6), length of junctional epithelium (7), and area of collagen scaffold (8). The line connecting the notches (N) is defined as apical bottom of the defect.

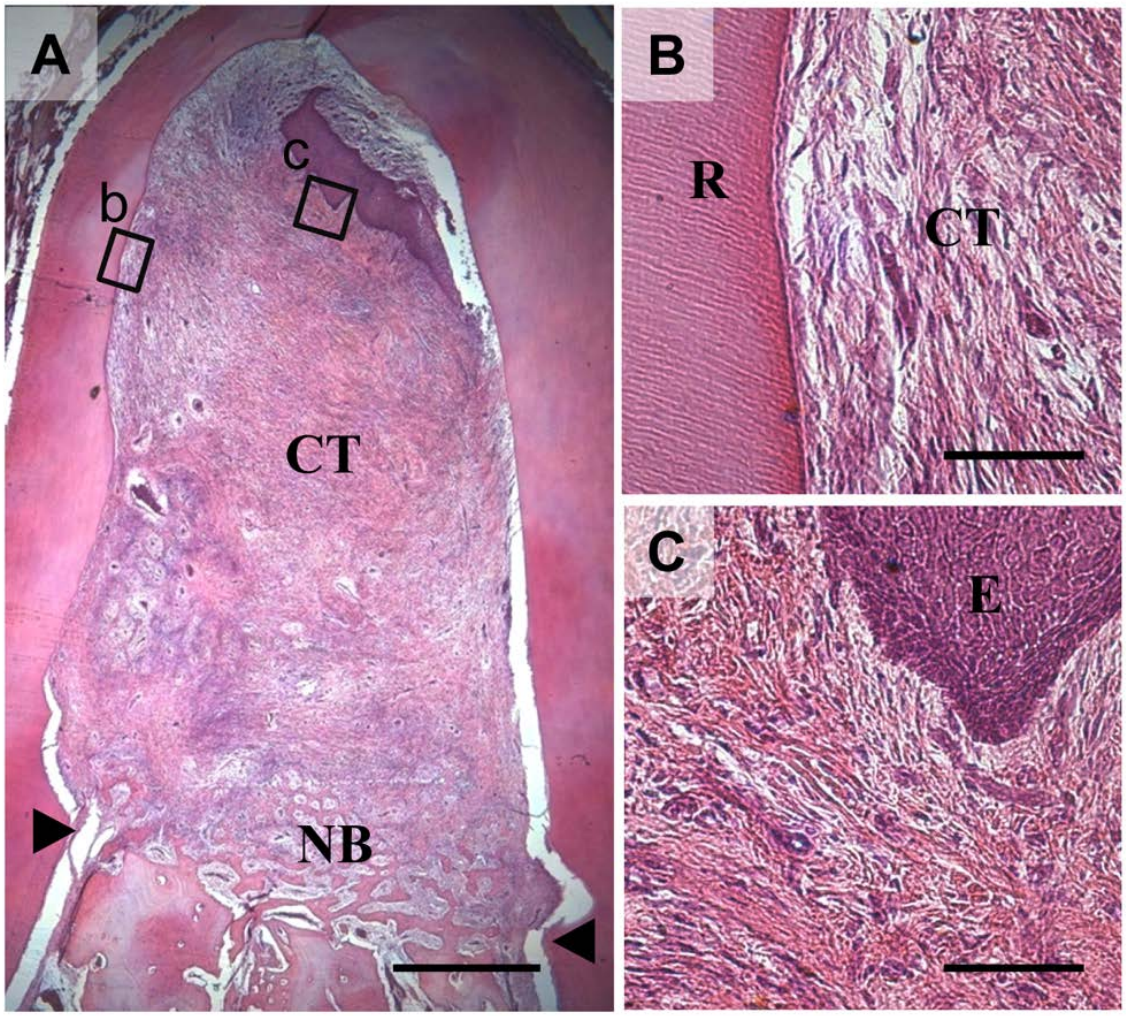

Figure 4. Histological findings of control group at 2 wk. A) Newly formed granulation tissue occupied the defect. New bone formation was slightly observed. The apical notches are indicated by arrowheads. B) Higher magnification of the framed area (b) in A. Connective tissue is seen attached to root surface, however, cementum and periodontal ligament were not formed at the coronal portion. C) Higher magnification of the framed area (c) in A. Epithelial tissue was observed at the coronal portion of the defect. Abbreviations: R, root; NB, new bone; CT, connective tissue; and E, epithelial tissue. Scale bars represent 1 mm (A), and 100 µm (B, C). Staining: HE.

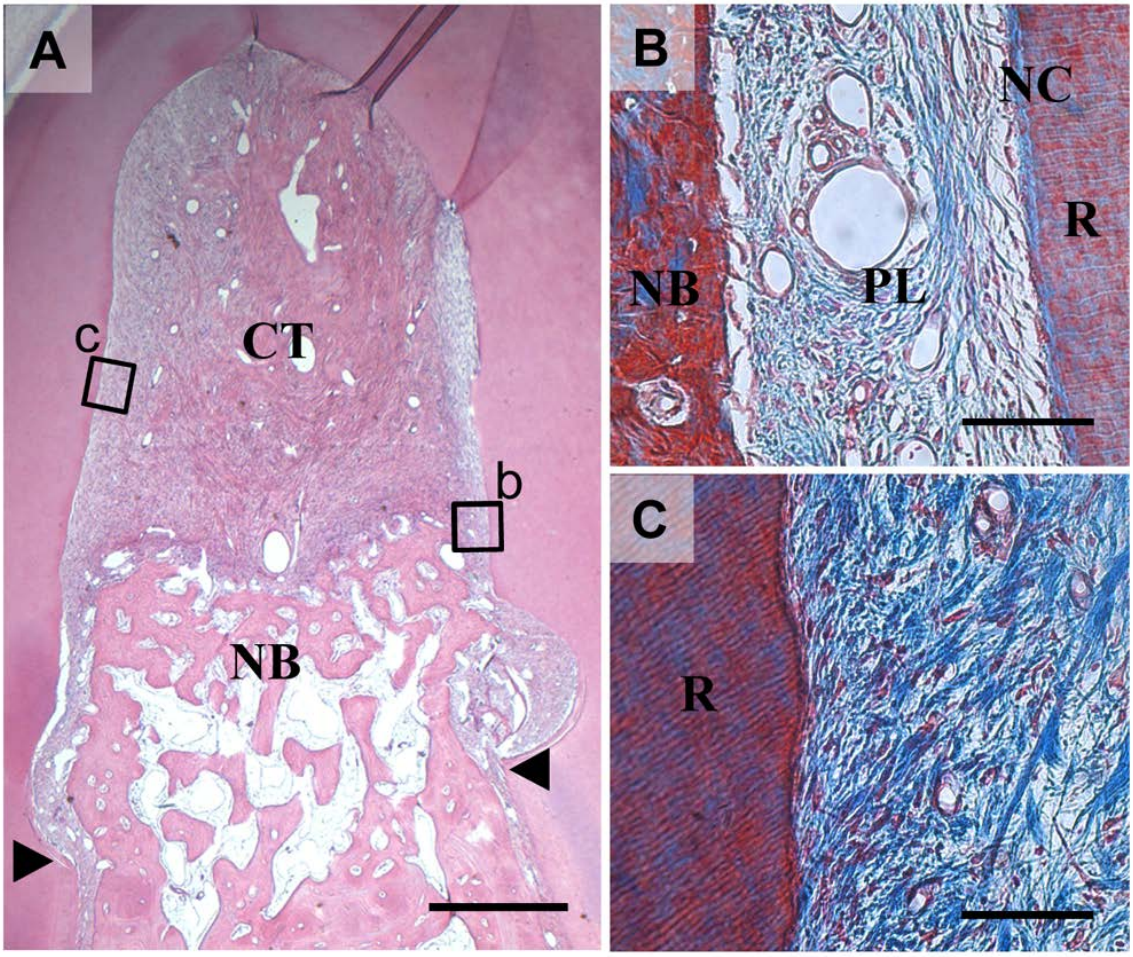

Figure 5. Histological findings in the control group at 4 wk. A) Alveolar bone formation was evident, however, in the coronal portion, connective tissue filled the furcation defect. The apical notches are indicated by arrowheads. B) Higher magnification of the framed area (b) in A. Periodontal ligament between new bone and cementum was formed in the apical portion of the furcation defect. C) Higher magnification of the framed area (c) in A. Connective tissue attached to root surface without cementum-like tissue deposition. Abbreviations: R, root; NB, new bone; CT, connective tissue; NC, new cementum; and PL, periodontal ligament. Scale bars represent 1 mm (A), and 100 µm (B, C). Staining: HE (A), and Masson's trichrome (B, C).

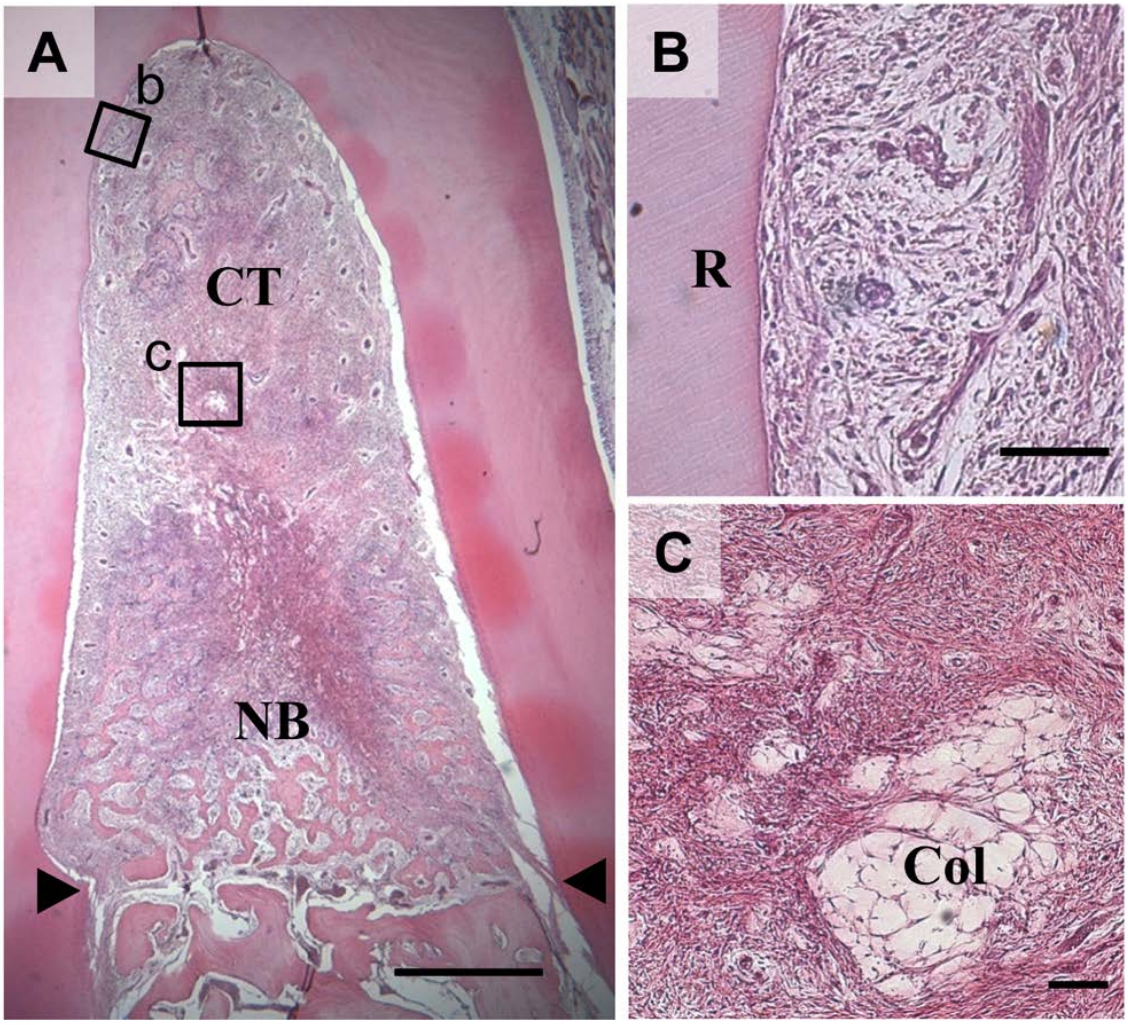

Figure 6. Histological findings at 2 wk in the experimental group. A) The furcation defect was filled with cell-rich connective tissue. Alveolar bone induction was frequently exhibited continuing from pre-existing bone. The apical notches are indicated by arrowheads. B) Higher magnification of the framed area (b) in A. Numerous fibroblastic and osteoblastic cells were observed in the connective tissue attached to root dentin surface. C) Higher magnification of the framed area (c) in A. Proliferation of fibroblastic cells was demonstrated at the inner part of the collagen hydrogel/sponge scaffold, suggesting that degradation of collagen material was in progress. Few inflammatory cells were seen around the residual collagen hydrogel/sponge scaffold. Abbreviations: R, root; NB, new bone; CT, connective tissue; and Col, collagen hydrogel/sponge scaffold. Scale bars represent 1 mm (A), and 100 μm (B, C). Staining: HE.

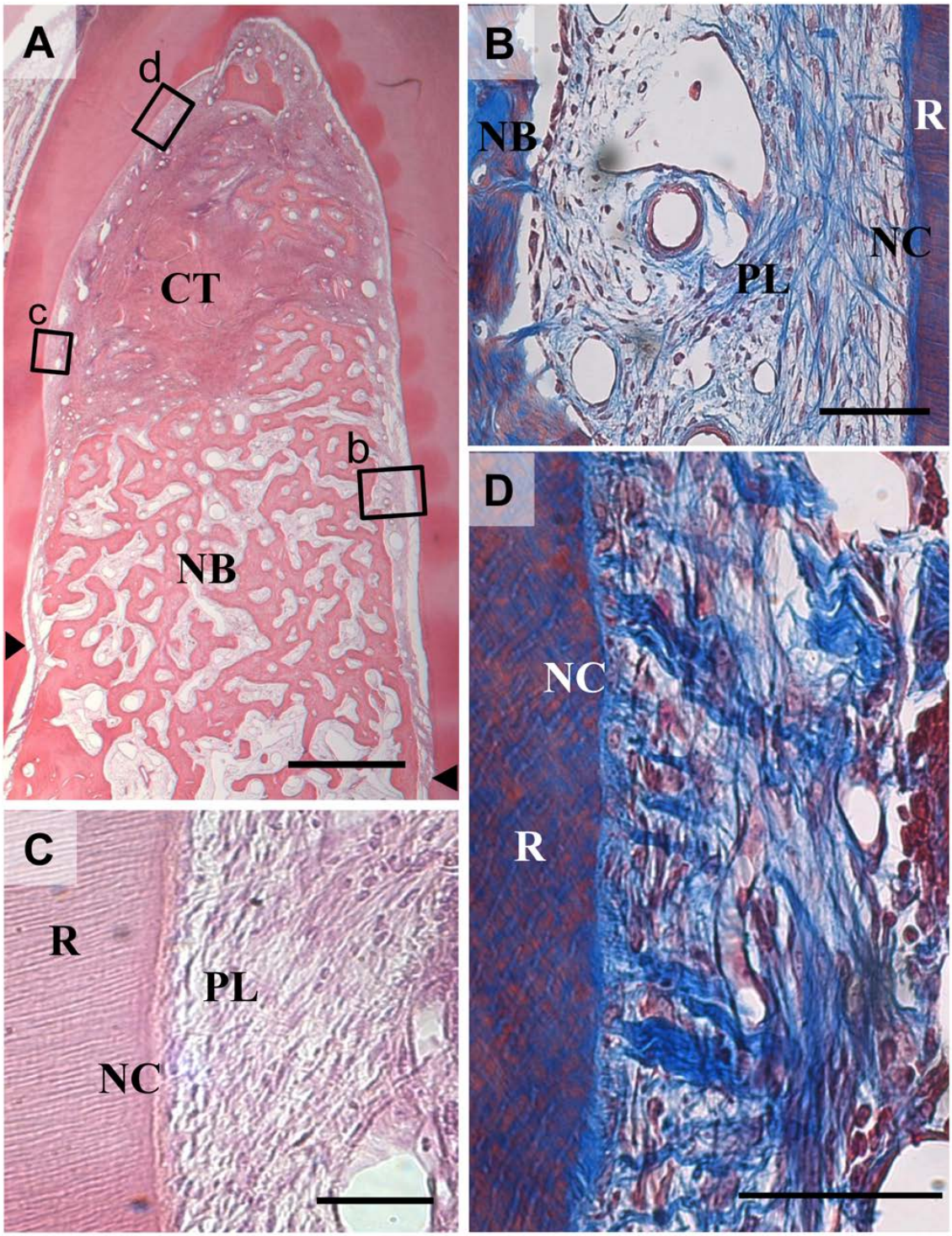

Figure 7. Histological findings at 4 wk in the experimental group. A) New bone formation was advanced at the furcation defect. The apical notches are indicated by arrowheads. B) Higher magnification of the framed area (b) in A. Structure of periodontal ligament with oriented fibers between cementum and alveolar bone was reconstructed. Connective tissue fibers were inserted into newly formed cementum and

alveolar bone resembling Sharpey's fibers. C) Higher magnification of the framed area (c) in A. Thin layered cementum-like tissue was detected on the root surface. D) Higher magnification of the framed area (d) in A. Collagen fibers oriented perpendicularly to the root surface were frequently exhibited at the coronal portion. Abbreviations: R, root; NB, new bone; CT, connective tissue; NC, new cementum; and PL, periodontal ligament. Scale bars represent 1 mm (A), and 100 µm (B-D). Staining: HE (A, C), and Masson's trichrome (B, D).